saint

KLINIKUM Passau

Nieren-PTA & Stenting
Materialien & Technik

Josef Tacke
Institut für Diagnostische
und Interventionelle
Radiologie/Neuroradiologie
Klinikum Passau

GEFÄSSZENTRUM
Passau

zertifiziert durch

Deutsche Röntgengesellschaft

Deutsche Gesellschaft für Gefäßchirurgie

Hypertonie

Definition nach WHO

- Systolischer RR > 160 mmHg
- Diastolischer RR > 95 mmHg

renovaskuläre Hypertonie

- nur 3-5% aller Hypertonieformen

Zierler Am J Hypertens1996

renovask. Hypertonie

Arteriosklerose (ca. 90%)
Fibromuskuläre Dysplasie (FMD)
Arterienverschluß, -embolie
AV-Fistel
externe Nierenkompression
Neurofibromatose, Arteriitis
iatrogene NAST (Radiatio, Re-Stenose)

renovask. Arteriosklerose

Plaques der Aortenwand

- meistens ostiale Stenosen

progressive Erkrankung

- 18% Okklusion/5 Jahre (auch nicht betr. Gefäße)

hohe Korrelation mit Nierenatrophie

Caps Kidney Int 1998 Taylor Clin Radiology 1997

klinische Manifestation NAST

Hypertonie (s. Goldblatt Mechanismus)

- junge Patienten mit FMD

LV Dysfunktion

- LV Hypertrophie
- myokardiale Fibrose (Aldosteron)

Niereninsuffizienz

Caps Kidney Int 1998 Taylor Clin Radiology 1997

Goldblatt-Mechanismus

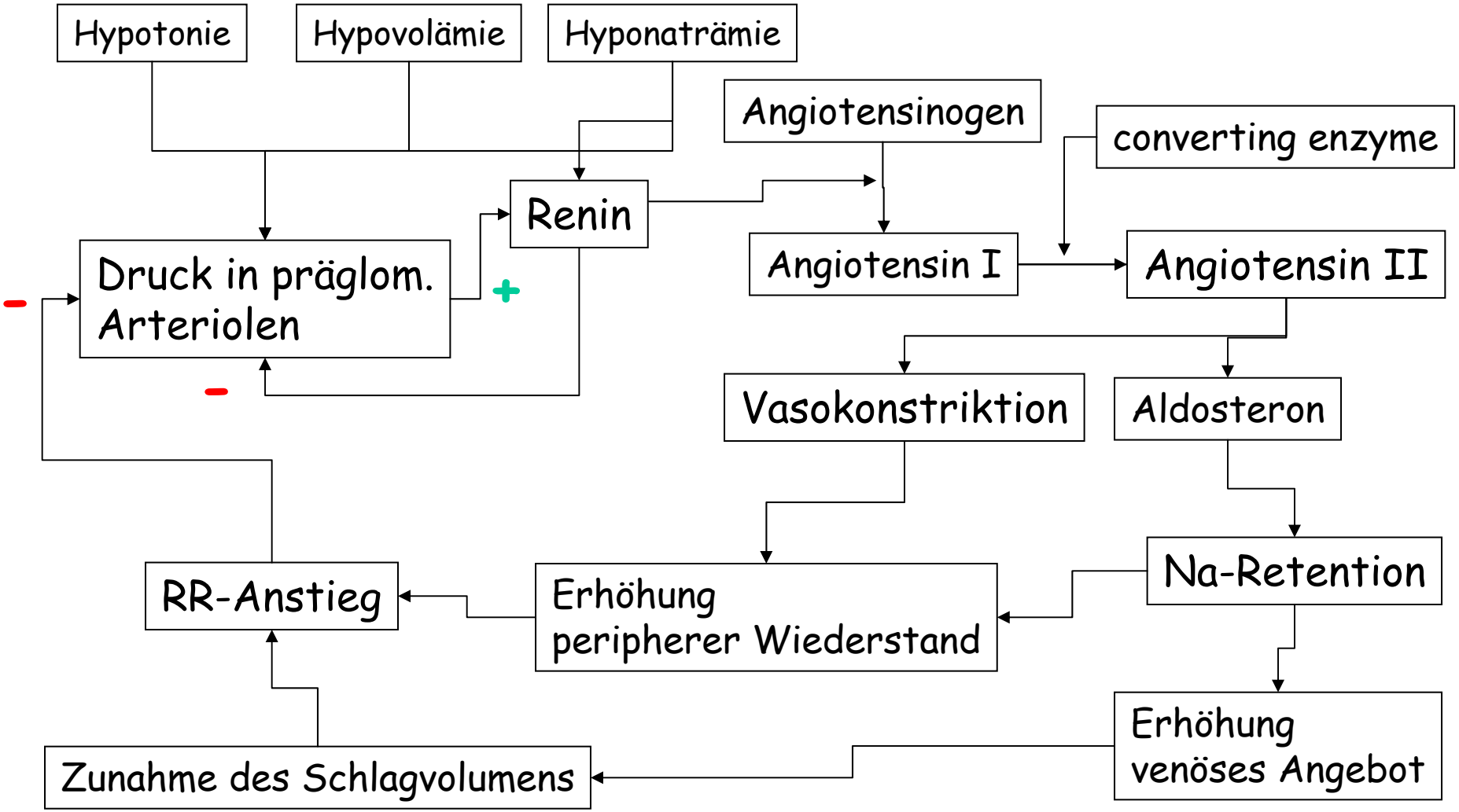

Diagnose NAST

Duplexsonographie

- direkter Stenosenachweis
- Vmax > 200 cm/s
- RI 0.05

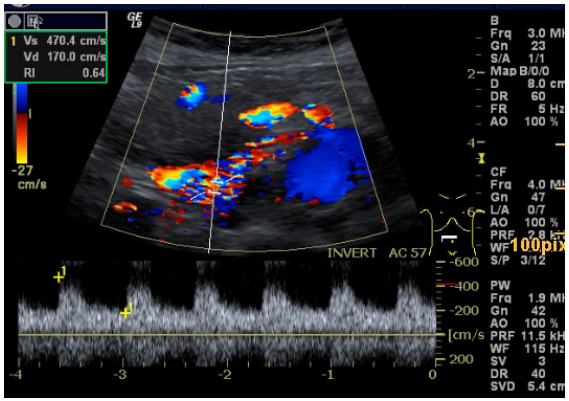

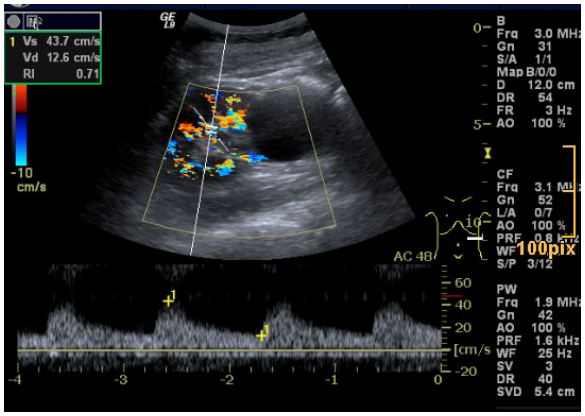

MR, CT Angio

Technik

Prämedikation

- 4x 75 mg Clopidogrel
- ASS 100 mg
- RR-Medikamente einnehmen
- 5000 IE Heparin

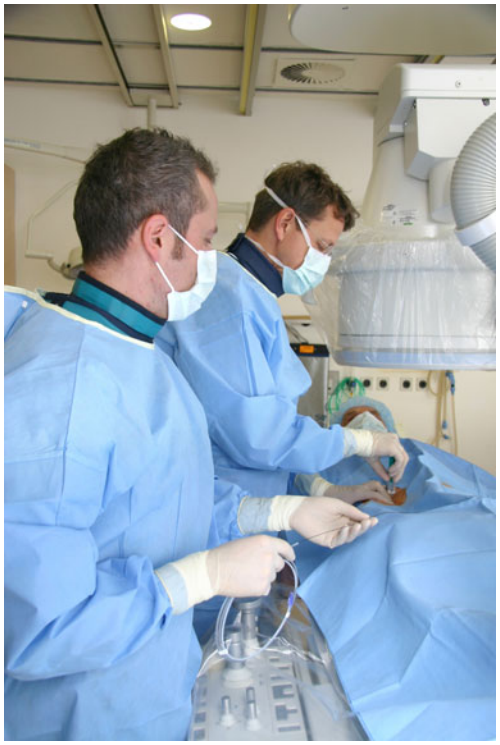

Überwachung

- RR, EKG

Kontrastmittel

- wenn GFR < 60 ml/min, hydrieren
- wenig KM

Technik

Planung!

Technik

Zugang?

femoral Standard

brachial bei Leriche oder spitzem Abgang

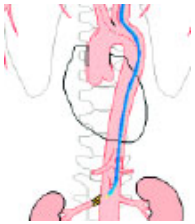

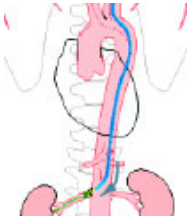

Führkatheter?

bei Monorail >> OTW 5 - 6F

Vorteil:
- sicherer Zugang
- Angio jederzeit

Nachteil:
(Kosten)

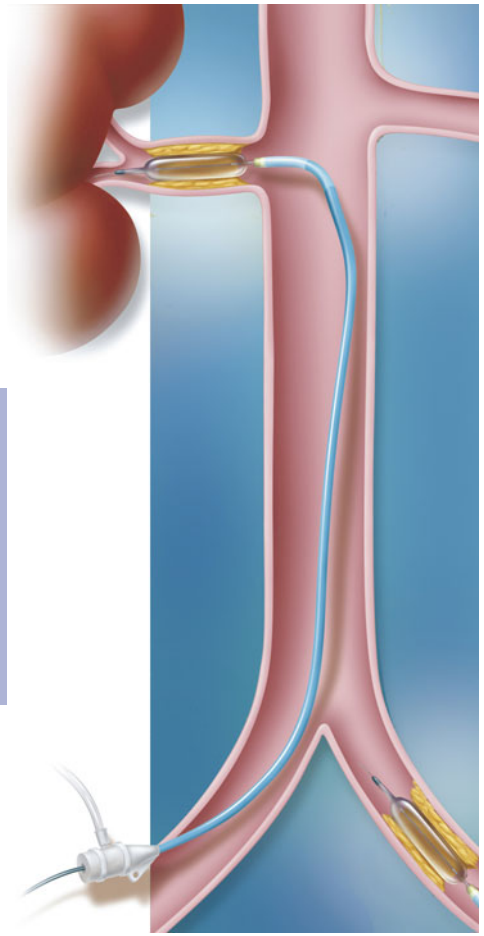

OTW?

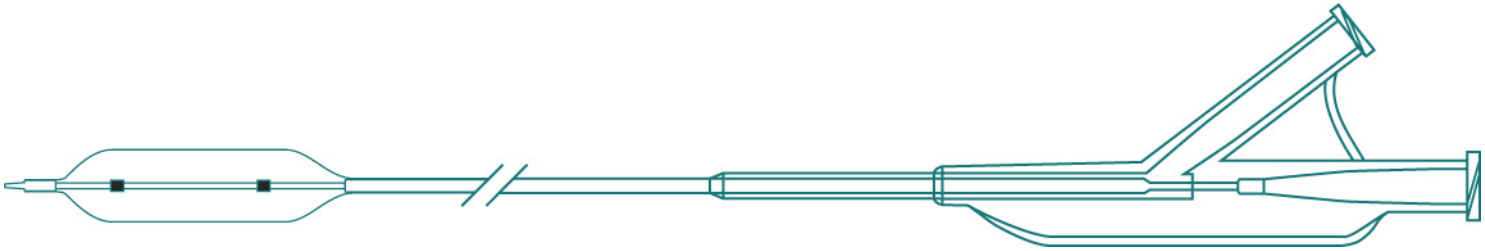

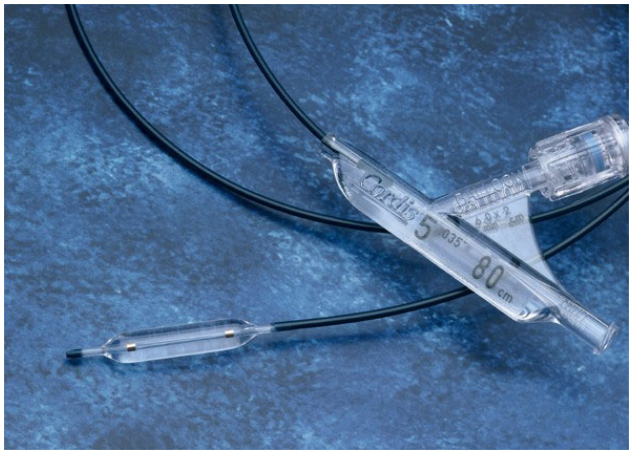

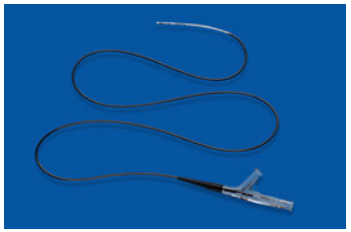

Monorail (rapid exchange)!

0,014 Inch Draht
2-8 mm Durchmesser

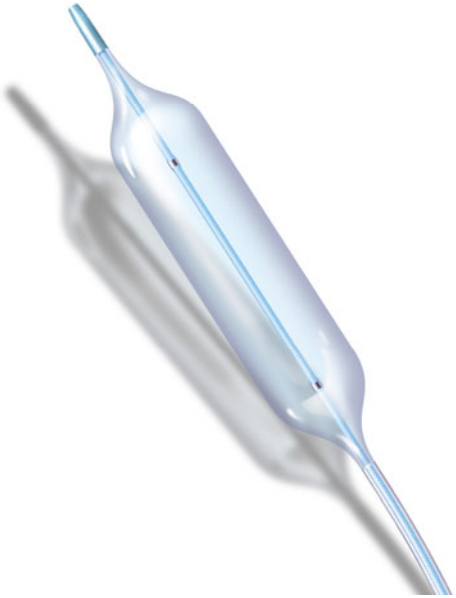

Technik

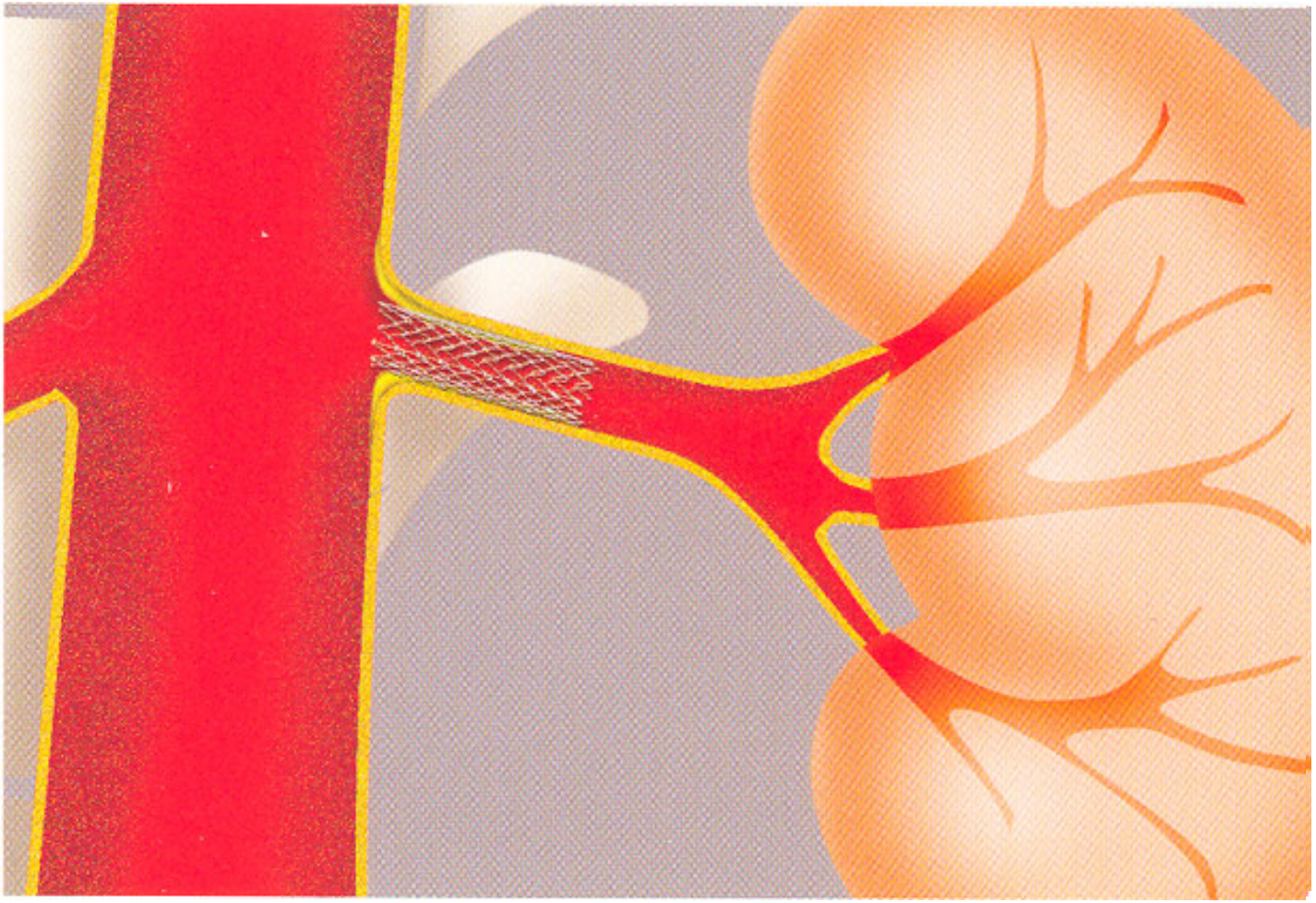

Monorail (rapid exchange)

Monorail vs. OTW

63 Pat. (78 Prozeduren, 46 OTW u.32 RX); retrospektiv

	OTW	RX	
Durchleuchtung	**13,1 Min.**	**11,1 Min.**	ns
Techn. Erfolg	**94%**	**97%**	ns
Komplikationen	**24%**	**6%**	P=.04
KM-Verbrauch	**215ml**	**140ml**	P<.001
Krea.-Anstieg	**20%**	**3%**	P=.041

Amighi et al.: J Endovasc Ther 2005



oder



?

Innovation

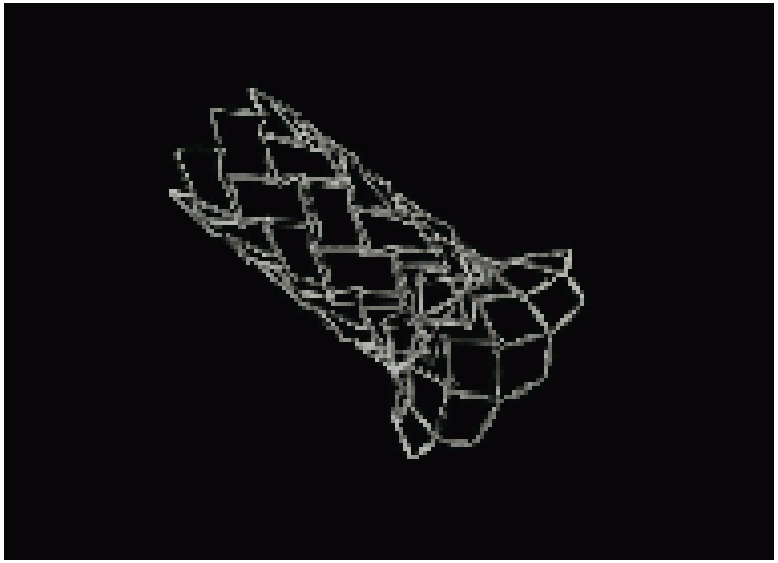

SQUARE ONE™
ARCHSTENT™ OSTIAL SYSTEM

PTA
Plaquesprengen, Dehnung, Einriss

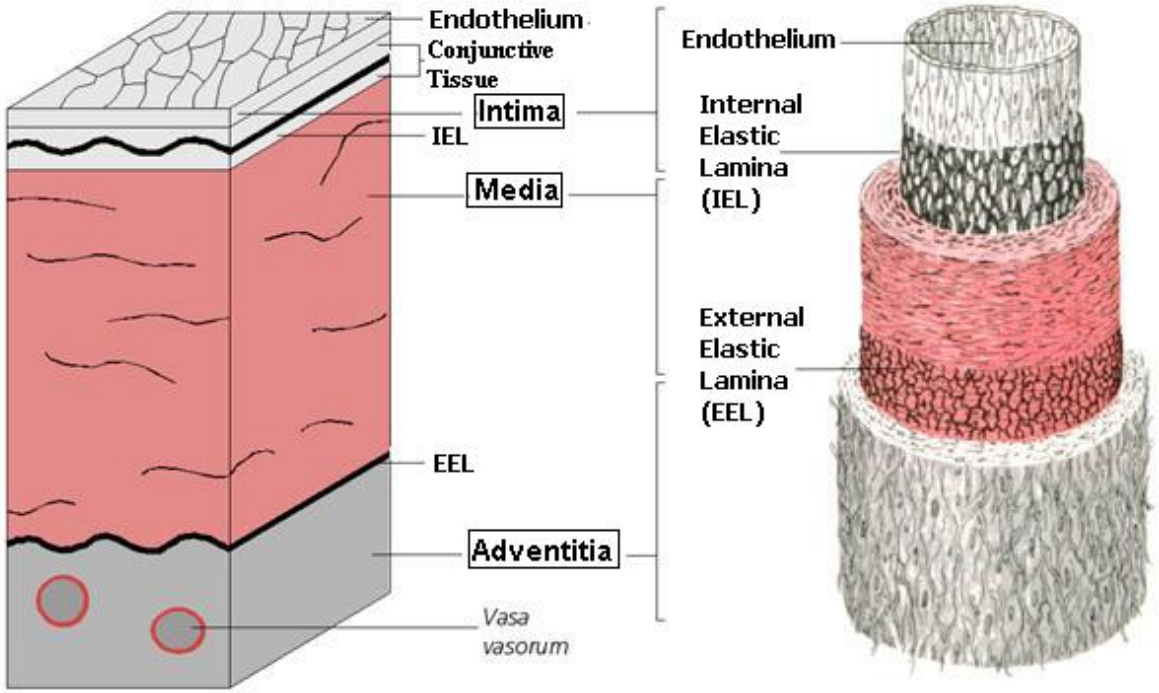

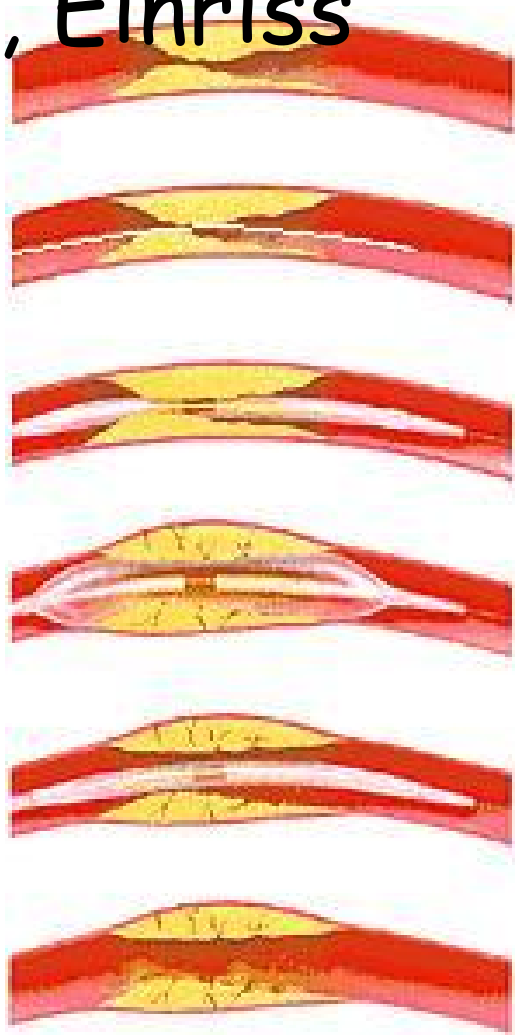

PTA



bei FMD

Stent KI!

ostiumferne Stenose

Instentstenose

FMD
14.2.06

PTA



bei FMD

Stent KI!

ostiumferne Stenose

Instentstenose

FMD
20.4.06

Fibromuskuläre Dysplasie

	Birrer 2002	Surowiec 2003	Alhadad 2005
Patienten	27	14	69
FU (Monate)	10±4 (mean)	24-96	84±57 (mean)
Prim. Offenheit			
1 Jahr	77%	83%	73%
8 Jahre		69%	67%
Stent	1 Pat.	0 Pat.	5 Pat.

Atherosklerotische Stenosen

163 Pat. (200 Stenosen); prospektiv; FU (median): 12 Monate

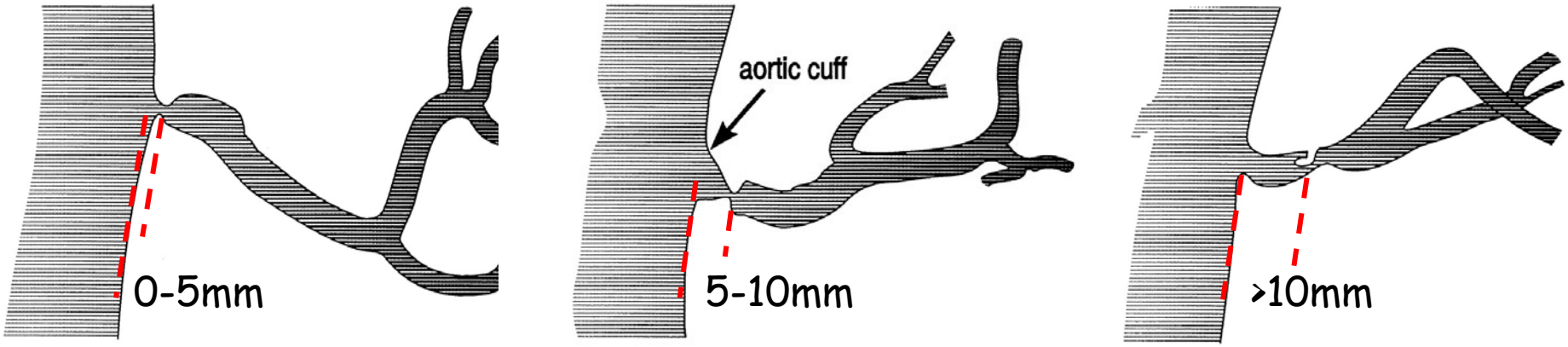

ostial	proximal	truncal
29%	50%	21%

Baumgartner et al.: Radiology 2000

PTA



bei FMD

Stent KI!

ostiumferne Stenose

Nachteil

Dissektion

periphere Embolie

PTA



bei FMD
Stent KI!
ostiumferne Stenose
Instentstenose

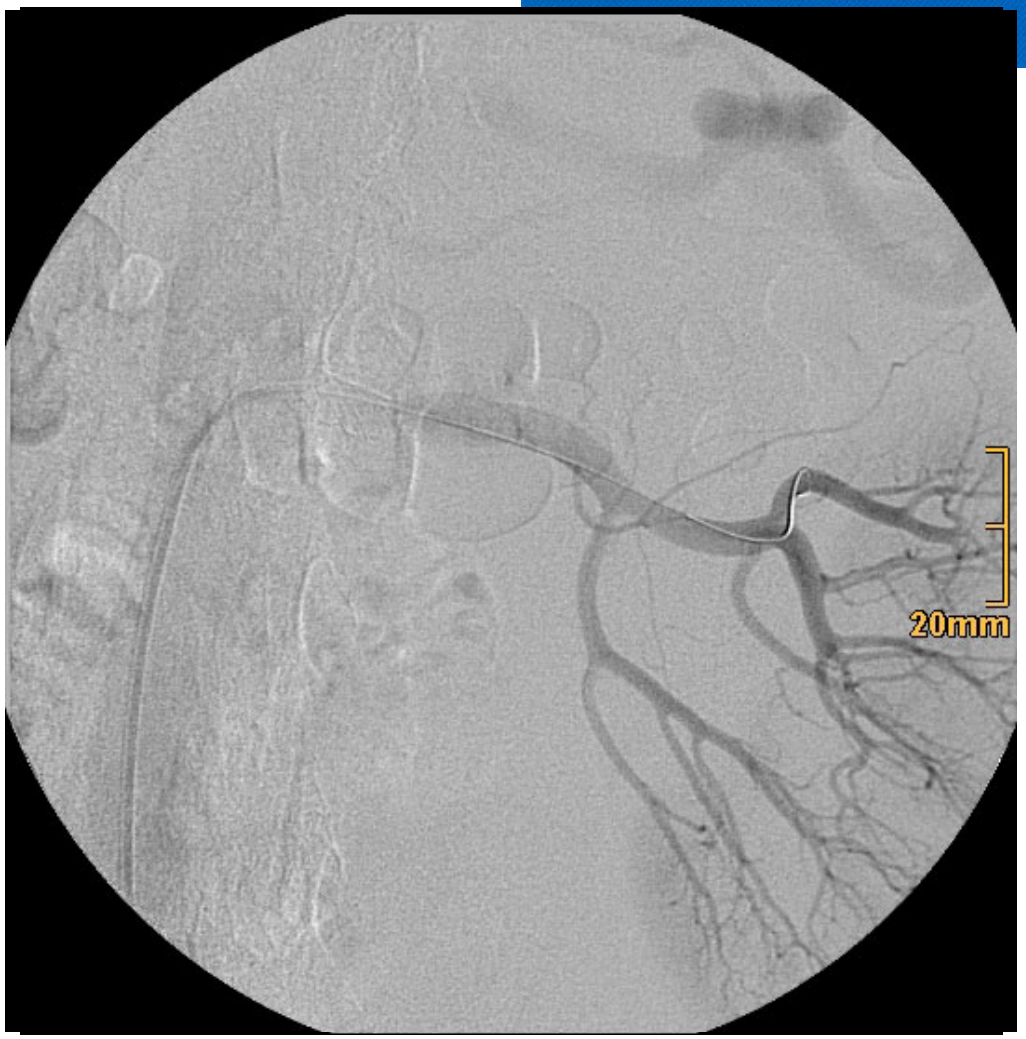

Z.n. Stent li
Vor 3 Jahren
Schrumpfniere re

Stent-PTA



Verschluß
Ostiale Stenosen
Kalk
Exzentrische St.
Dissektion

Stent-PTA



Verschluß
Ostiale Stenosen
Kalk
Exzentrische St.
Dissektion

Stent-PTA

Verschluß
Ostiale Stenosen
Kalk
Exzentrische St.
Dissektion

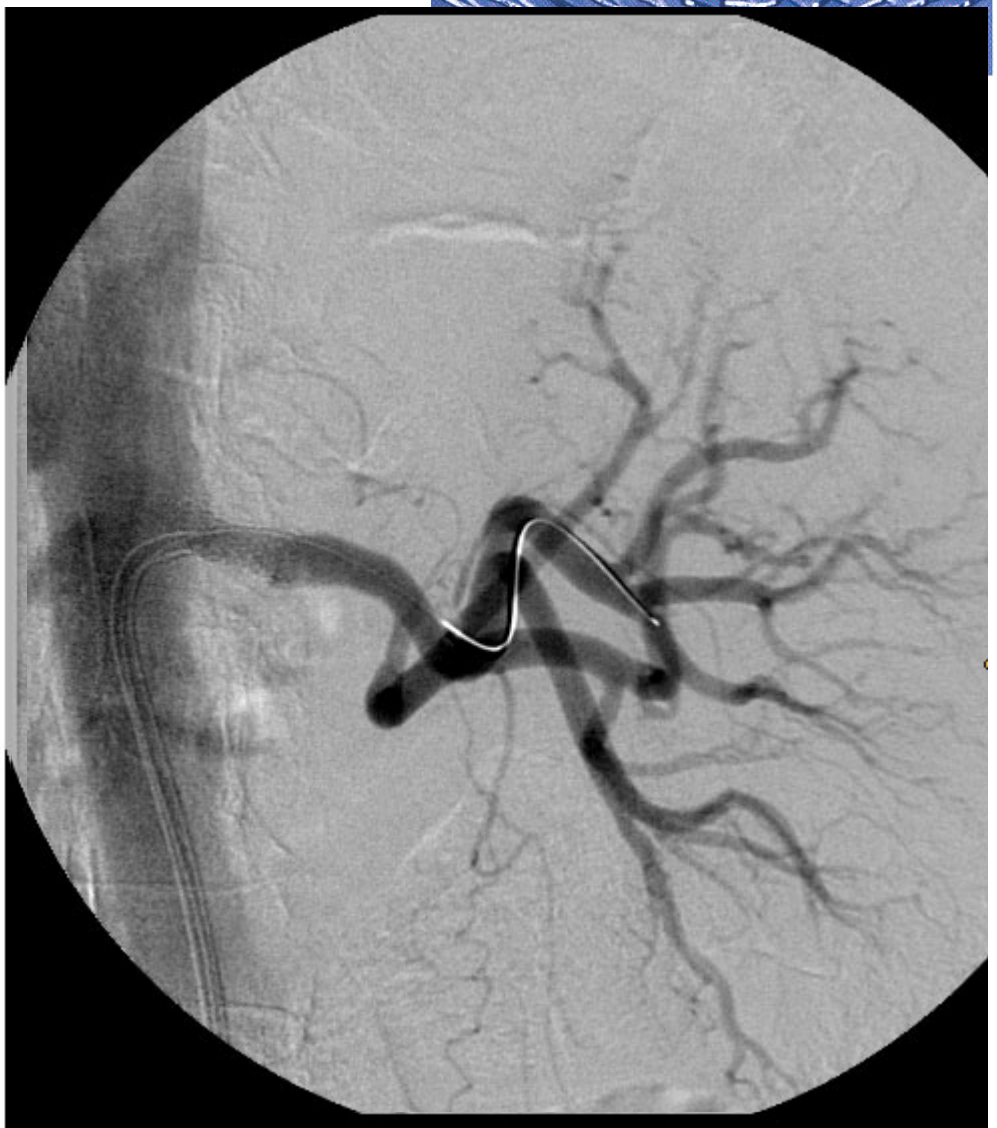

saint

KLINIKUM Passau

Stent-PTA



Verschluß
Ostiale Stenosen
Kalk
Exzentrische St.
Dissektion

beidseits?



Hypertonie
Stenose
bds.

dreifach?



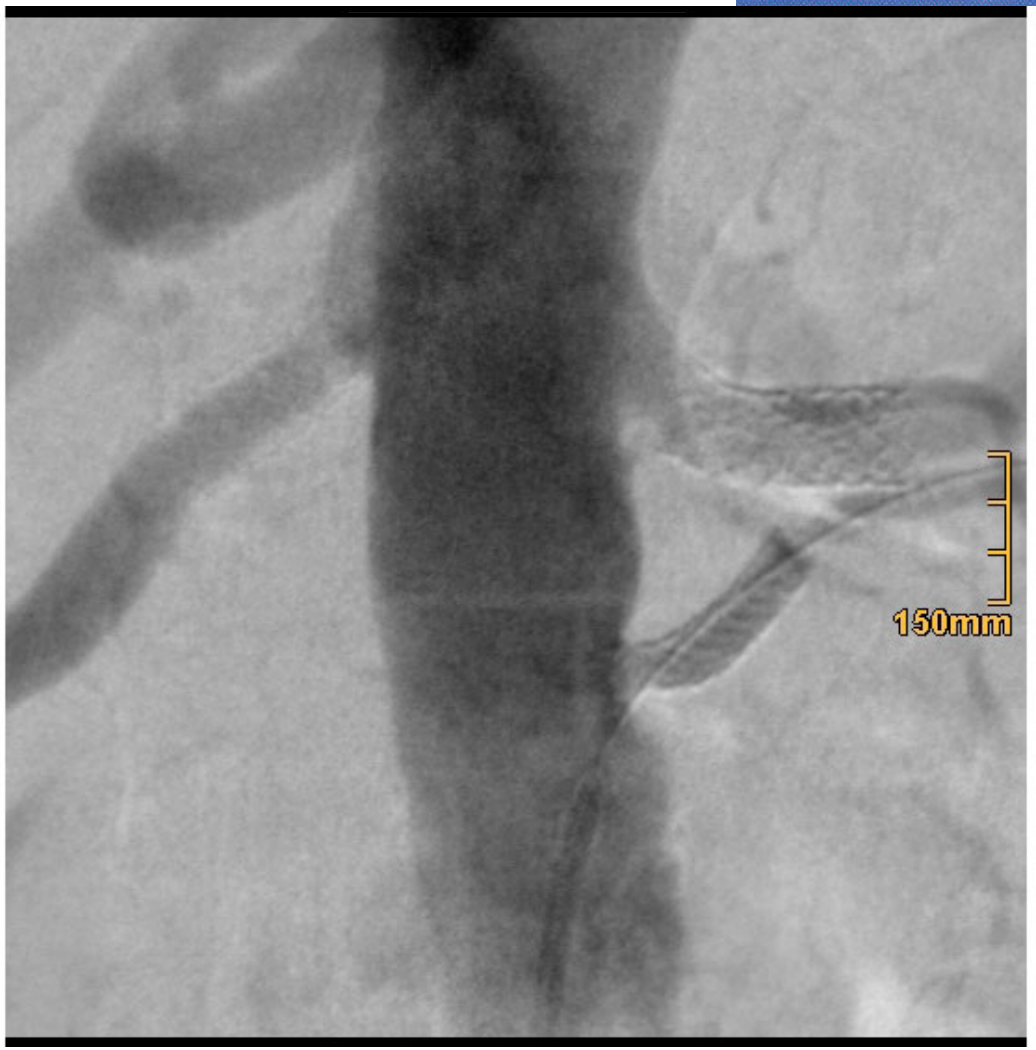

Z.n. Stent re
Stenose li
Unterpol li

technische Ergebnisse

Stent >> PTA

- ostiale Stenosen
- technischer Erfolg 100% vs 77%

2 randomisierte Studien

Van de Veen et al.: Arterial stenting and ballon angioplasty in ostial atherosclerotic renovascular disease: a randomised trial. **Lancet 1999**

Plouin et al.: Blood pressure outcome of angioplasty in atherosclerotic renal artery stenosis: a randomized trial. The EMMA study group. **Hypertension 1998**

Rezidiv-Stenose nach Stent

300 Pat. (363 Stents), FU: 16 Mo. (Median)

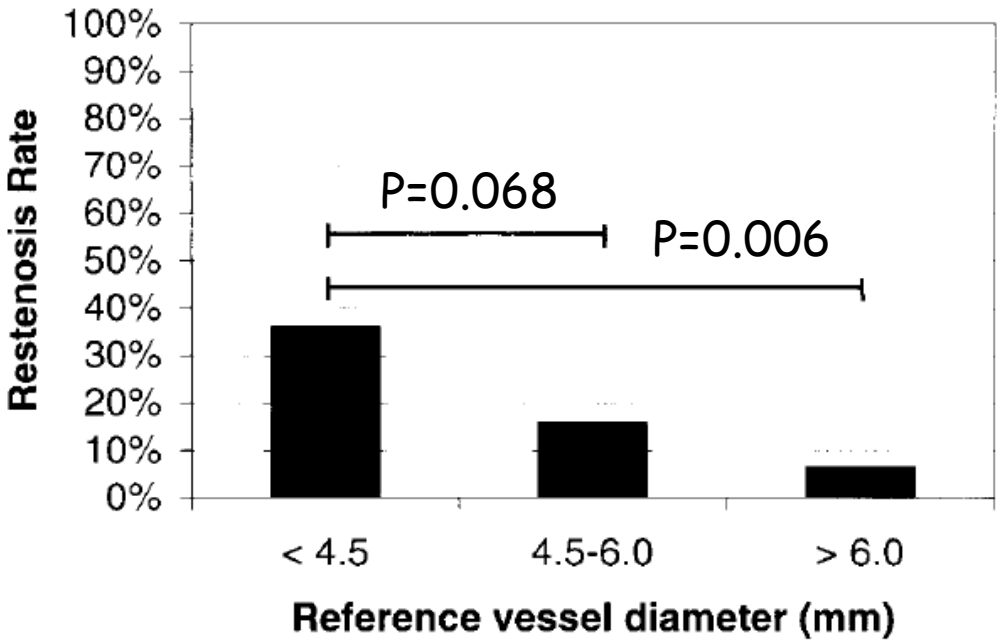

Restenose-Rate nach 10 Monaten (mean)

- 21% (23/102 Pat.)
- 12% bei ø >4,5mm

Lederman et al.: Am Heart J 2001

klinische Ergebnisse

Beschichtete Stents?

geklaut bei Afshin Gangi

geklaut bei Afshin Gangi

Beschichtete Stents?

- Carbon-Beschichtung:

  Restenoserate: 6,4% (coated) vs. 5,8% (bare) P>.05

  (147 Pat. FU: 22±5Mo.)

  Zeller et al.. J Endovasc Ther 2005

- Gold-Beschichtung:

  1-Jahres-Offenheit: 69% (coated)vs. 84% (bare) P<.05

  (126 Pat. FU: 15 Mo.)

  Nolan et al.. J Vasc Surg 2005

- Sirolimus Coating

  50% Restenose : 8% (coated) vs. 14% (bare) P>.05

  (102 Pat. FU: 6 Mo.)

  Sapoval et al.. JVIR 2005

Exotica



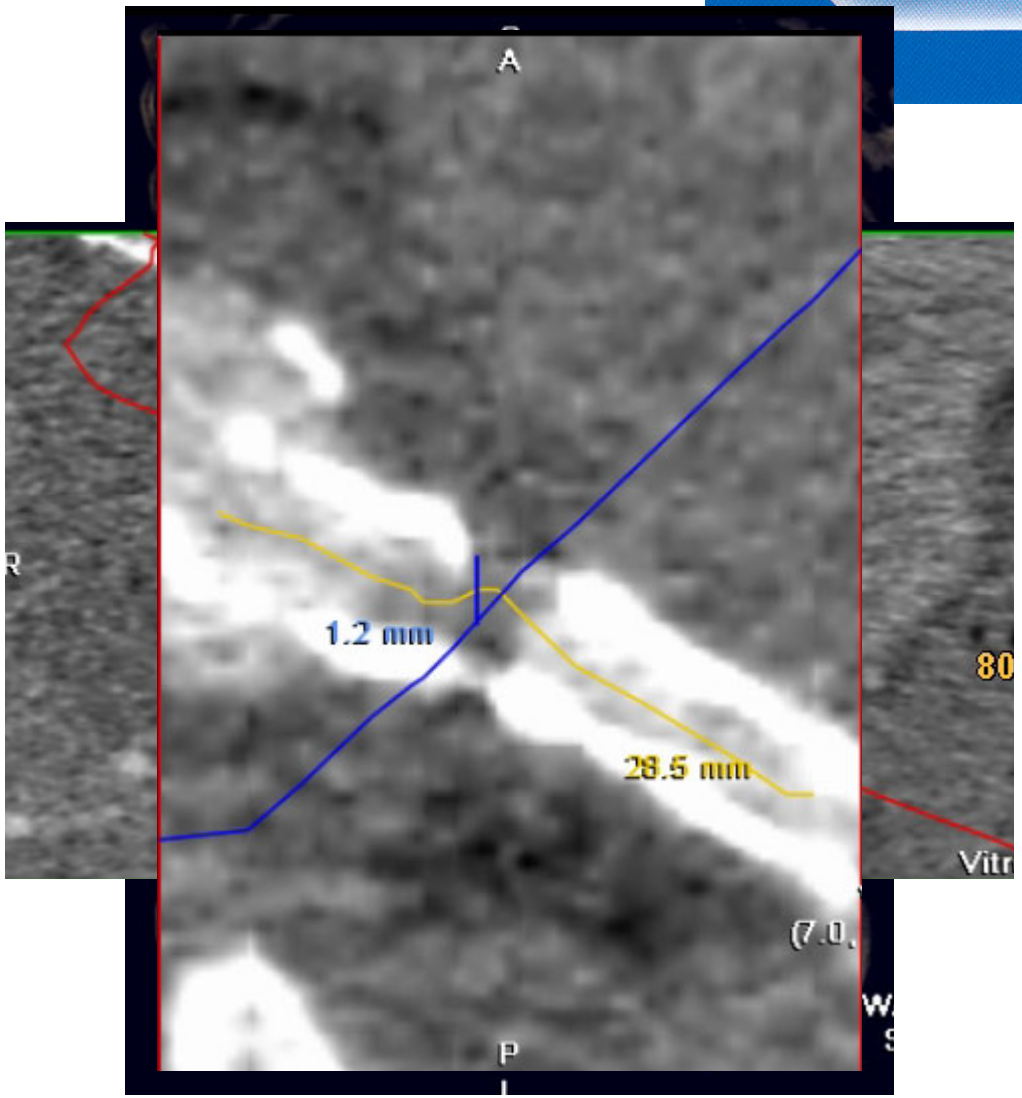

2x Stent li
Y-Prothese
Bypass li
erneute NAST

Exotica

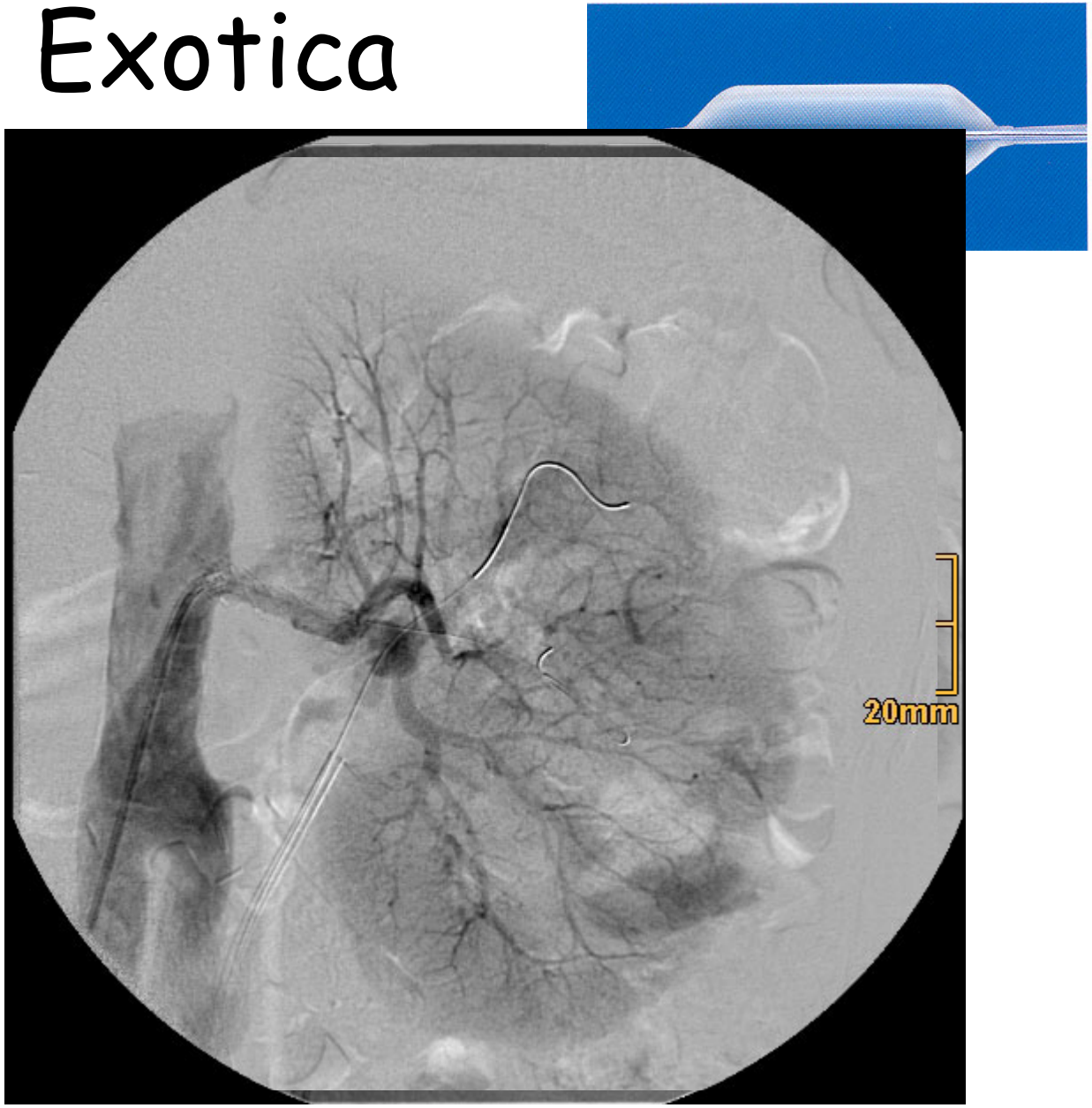

2x Stent li
Y-Prothese
Bypass li
erneute NAST

Zusammenfassung

- Indikationsstellung!
- bei FMD nur PTA
- Führkatheter, Rx-Systeme Standard
- Stent-PTA zentral besser als PTA
- duale Plättchenhemmung



Benedetta Bionichi

josef.tacke@klinikum-passau.de

KLINIKUM Passau

IROS

13.1. -15.1.2010

DeGIR Deutsche Gesellschaft für Interventionelle Radiologie und minimal-invasive Therapie